Radiology Advances, 2025, **2(3)**, umaf007
https://doi.org/10.1093/radadv/umaf007
Advance access publication: February 12, 2025
Review

Mitigating overtreatment of ductal carcinoma in situ

Hannah L. Chung, MD[1,*], Tanya W. Moseley, MD[2,*], Dulcy E. Wolverton, MD[3], Gary J. Whitman, MD[4]

[1]Diagnostic Radiology, Breast Imaging Section, Utah Imaging Associates, LLC, Farmington, UT 84025, United States
[2]Department of Radiology, University of Mississippi Medical Center, Jackson, MS 39216, United States
[3]Department of Radiology, CU Anschutz Medical, Aurora, CO 80045, United States
[4]Breast Imaging Department, MD Anderson Cancer Center, Houston, TX 77030, United States

*Corresponding author: Hannah L. Chung, MD, Diagnostic Radiology, Breast Imaging Section, Utah Imaging Associates, LLC, 433 North 1075 West, Suite 104, Farmington, UT 84025, United States (hchung@utahimaging.com); Department of Radiology, University of Mississippi Medical Center, Jackson, MS 39216, United States (tmoseley@umc.edu).

Abstract

Ductal carcinoma in situ (DCIS) represents a pathologic continuum between a high-risk lesion of the breast and an invasive cancer. Because death from breast cancer is linked to its metastatic spread, the major significance of DCIS is its potential to progress to an invasive cancer and the risk of an occult invasive cancer unrecognized until surgical excision is performed. The standard of care management for DCIS is a minimum of surgical excision, often coupled with adjuvant treatments. For approximately half of the DCIS cases that are at low risk for progression, standard-of-care treatment represents a potential overtreatment and the source of one of the main criticisms against screening. To minimize overtreatment, the tumor biology of any individual's DCIS should be considered in the context of the patient's age, medical comorbidities, and tolerance for risk to tailor personalized treatments. Just as the management of some high-risk lesions of the breast have evolved to include nonsurgical options, it makes sense to personalize the management offered to patients with DCIS. This article reviews the epidemiology, imaging, pathology, ongoing trials, current and possible future treatments of DCIS, comparing and contrasting it with classic high-risk breast lesions and invasive breast cancers.

Keywords: ductal carcinoma in situ, active surveillance, high risk lesion of the breast, overdiagnosis, overtreatment

Abbreviations

ADH = atypical ductal hyperplasia; CEM = contrast-enhanced mammography; DCIS = ductal carcinoma in situ; ER = estrogen receptor; HER2 = human epidermal receptor 2; ALH = atypical lobular hyperplasia; LCIS = lobular carcinoma in situ; NCCN = National Comprehensive Cancer Network; RRt = residual risk subtype; SLNB = sentinel lymph node biopsy

Summary

The heterogeneity of ductal carcinoma in situ (DCIS) dictates personalized treatment so that low-risk DCIS is not overtreated and high-risk DCIS is treated appropriately to prevent progression to invasive cancer.

Key Results

- Breast ductal carcinoma in situ (DCIS) represents a continuum between a high-risk lesion and a nonobligate precursor to invasive cancer.
- While the current standard-of-care treatment for DCIS effectively cures the disease, it may represent overtreatment in a significant portion of cases that are at low risk for progression to an invasive cancer.
- The results of multiple active surveillance clinical trials are expected to help guide future management safely and effectively.

Introduction

Ductal carcinoma in situ (DCIS) represents a proliferation of neoplastic cells confined within the basement membrane, without invasion of the myoepithelial layer. Although DCIS is considered a form of breast cancer, unlike an invasive cancer, there is not the potential to metastasize beyond the breast and cause harm to the patient's health and life. The true incidence of DCIS is unknown as approximately 90% of DCIS cases are asymptomatic,[1] with the majority of DCIS cases diagnosed at screening mammography, an examination that many women choose not to participate in. According to the 2024 Breast Cancer Facts and Figures, there were 56 500 DCIS cases diagnosed in the United States, representing 18.2% of the total 339 250 breast cancers.[2] Furthermore, 8.9% of autopsy breast specimens demonstrate DCIS that were clinically undetected and irrelevant during the lifetime of that individual.[3]

Pathophysiology of DCIS—what is known and not known

Because death from breast cancer is linked to an invasive cancer's metastatic spread, DCIS is clinically significant because of this risk of progression to an invasive cancer in the future as

Received: October 1, 2024; **Revised:** January 21, 2025; **Accepted:** February 6, 2025
© The Author(s) 2025. Published by Oxford University Press on behalf of the Radiological Society of North America.
This is an Open Access article distributed under the terms of the Creative Commons Attribution-NonCommercial License (https://creativecommons.org/licenses/by-nc/4.0/), which permits non-commercial re-use, distribution, and reproduction in any medium, provided the original work is properly cited. For commercial re-use, please contact reprints@oup.com for reprints and translation rights for reprints. All other permissions can be obtained through our RightsLink service via the Permissions link on the article page on our site—for further information please contact journals.permissions@oup.com.

well as the presence of a coexisting occult invasive cancer that would be missed should immediate surgical excision not be performed. The natural history of untreated DCIS is unknown because most patients understandably choose the full spectrum of treatments offered to them, especially as the name of the disease includes "carcinoma." In fact, 97% of DCIS lesions undergo immediate surgical excision.[4] However, in the rare scenario of untreated DCIS, originally thought to represent benign disease, Sanders and Page reported that during a follow-up interval of greater than 40 years, 36%–39% developed an invasive cancer in the same breast quadrant of the original DCIS at a median follow up of 31 years.[5,6] Similarly, Rosen and colleagues reported that at least 39% of untreated DCIS cases developed clinically evident cancer, usually an invasive cancer at the site of untreated DCIS.[7] These early pathology studies suggest that DCIS is indeed a precursor lesion to an invasive cancer, albeit in some patients, the progression may be indolent occurring in the distant future, whereas in others, DCIS may be clinically significant and potentially already invasive at the time of diagnosis.

The relationship between DCIS and invasion is not fully understood. In cases of concurrent DCIS and invasive cancer, identical genetic and molecular alterations have been observed in both the DCIS and invasive components.[8] Although there are different theories regarding the natural history of DCIS, this observation supports the multiclonal invasion model, in which certain clones of neoplastic cells may escape the basement membrane and migrate into the adjacent tissues to establish an invasive cancer. Lastly, the environment in which DCIS occurs may contribute to progression to an invasive cancer due to an interplay of fibroblasts, tumor infiltrating lymphocytes, and other factors.[9]

For the DCIS that is at low risk for progression, there is little clinical difference with classic high-risk lesions of the breast which are nonobligate precursors to breast cancer as well as markers of generalized increased risk for breast cancer. DCIS is also a nonobligate precursor to an invasive cancer. Per Surveillance Epidemiology and End Results data from 1992 to 2014, the 10-year risk of DCIS developing or progressing into an ipsilateral invasive carcinoma is 12.2% to 17.6%, dependent on the nuclear grade of the underlying DCIS.[10] Similarly, the 10-year risk of atypical hyperplasias developing into an invasive cancer is 14.6%.[11] Pathologic similarities between atypical ductal hyperplasia (ADH) and DCIS, in particular low-grade DCIS, are already recognized with differentiation of the 2 entities based on quantity. Similarly, the difference between the 2 kinds of lobular neoplasia, atypical lobular hyperplasia (ALH) and lobular carcinoma in situ (LCIS), is also based on quantity, namely less than 50% of the terminal duct lobular unit involvement by the abnormal neoplastic cells for ALH or greater than 50% for LCIS. DCIS and LCIS also share similar expressions of strong estrogen receptor (ER) positivity and negative basal cytokeratin markers (CK5, CK5/6, and CK14).[12] Despite these similarities and despite both having "carcinoma" in its name, DCIS is considered a cancer, whereas LCIS is not. Conversely, LCIS is considered a high-risk lesion, whereas DCIS is not.

Current management approach and ongoing dilemmas

For the DCIS that is at high risk for progression, surgical excision is indicated. Just as in a high-risk breast lesion where surgical excision helps to diagnose a coexisting, preinvasive DCIS or invasive cancer or simultaneously removes the high-risk lesion that may be the source of a future cancer development, surgical excision of DCIS is used to diagnose a coexisting invasive cancer or simultaneously removes the DCIS that may later develop into an invasive cancer. To understand the magnitude of potential overtreatment, the immediate surgical excision rate of 97% of all DCIS cases must be weighed against other factors, including the observed upstage rate at surgery as well as the immediate physical, psychological, and financial stresses related to treatment. According to a large meta-analysis of 52 studies involving 7350 DCIS cases, 25% of DCIS were upgraded and upstaged to an invasive cancer at the time of surgical excision.[13] This upgrade rate is similar to the 20%–29.5% upgrade rate of ADH to an invasive cancer[14] and the 38% upgrade rate of some lobular neoplasias, especially when imaging and pathology are discordant.[15]

As scientists have learned more about both benign and malignant diseases, the management of high-risk breast lesions has evolved to include multidisciplinary considerations, including patient factors, imaging, pathology, and the degree of sampling.[16,17] With this tailored approach, some high-risk lesions including some cases of ADH, which had historically all been recommended for surgical excision, are now being considered for imaging surveillance.[18–20] LCIS management has also evolved over time from surgical excision to no excision, to the current differential recommendations such that classic LCIS may be managed without surgical excision, whereas florid and pleomorphic variant forms of LCIS that demonstrate increased numbers of mitoses and necrosis are recommended for surgical excision.[21]

Ongoing surveillance trials

Accordingly, 4 international active surveillance clinical trials evaluating the outcomes of nonsurgical versus surgical treatment of low-risk DCIS cases have been developed (Table 1).[22–25] Thus far, the European low risk DCIS (LORIS and LORD) trials have had enrollment challenges, although with a major change to the study design, the LORD trial continues to enroll patients in the active surveillance arm only. The United States–based prospective, multicenter, randomized Comparison of Operative versus Medical Endocrine Therapy (COMET) trial is the first to complete enrollment with recently published results in December 2024. Study investigators reported that at a 2-year follow-up, women with low-risk DCIS undergoing active surveillance, with or without endocrine therapy, had the same rate of invasive cancer development as women who had standard, guideline concordant treatment with surgery.[22] The different trials vary in the definition of what constitutes low-risk DCIS, including disagreement on whether grade equates to risk. For example, low-grade DCIS diagnosed on biopsy of mammographic calcifications is the inclusion criteria for most of the active surveillance trials; however, the COMET and LORETTA trials also include cases of intermediate-grade DCIS.[22,25] The Japanese LORETTA trial is unique in its inclusion of noncalcified DCIS cases diagnosed on nonmammographic tests.[25]

It is difficult to predict the impact the surveillance trials will have on overall DCIS care. Based on a 2024 community hospital's application of the surveillance trials' eligibility criteria, 20% of DCIS patients would be considered low risk with an expected 7.2%–7.8% upgrade rate to an invasive

Table 1. Active surveillance clinical trials of breast ductal carcinoma in situ (DCIS).

Clinical trial name and design	Inclusion criteria	Exclusion criteria	Interventions in study arm	Lead country and enrollment status
COMET (Comparison of Operative versus Medical Endocrine Therapy) Multicenter randomized	≥40 years of age Low- or intermediate-grade DCIS diagnosed on biopsy of calcifications May include comedonecrosis	Symptomatic Synchronous IDC History of invasive cancer	Biannual mammography ± endocrine therapy Additional biopsies if imaging shows a new mass, distortion, asymmetry, or ≥5-mm increase in calcifications	United States of America Completed enrollment 2017–2023 Enrolled 484 patients to active surveillance and 473 patients to surgery Endpoint: 2-year risk of IDC
LORIS (Low Risk DCIS) Randomized	≥46 years of age Low- or intermediate-grade DCIS diagnosed on biopsy of calcifications	Symptomatic Comedonecrosis Synchronous IDC, BRCA1 or BRCA2 mutation	Annual mammography Additional biopsies if new suspicious finding per the radiologist or an increase in calcification measurement by 30%	United Kingdom Began enrollment in 2014 but closed in March 2020 after enrollment of 181 patients[a]
LORD (Low Risk DCIS) Initial design as a randomized control trial Later changed to a patient preference trial	≥45 years of age Low grade DCIS diagnosed on biopsy of calcifications	Symptomatic Comedonecrosis Synchronous IDC, BRCA1 or BRCA2 mutation	Annual mammography for 10 years Additional biopsies if imaging shows a new mass, asymmetry, or calcifications	Netherlands Ongoing enrollment Began enrollment in 2016 with dual arm randomization but changed in July 2020 to surveillance arm enrollment only[b]
LORETTA Observational Single-arm enrollment in surveillance with endocrine therapy	≥ 40 years of age Low- or intermediate-grade DCIS <2.5 cm in size May include calcified or noncalcified DCIS diagnosed by any modality	Symptomatic Comedonecrosis History of breast cancer, BRCA1 or BRCA2 mutation	Annual mammography + endocrine therapy (20 mg tamoxifen daily for 5 years)	Japan Actively recruiting since 2017 with target goal of enrolling 340 patients Endpoint: 5-year risk of IDC

[a]LORIS trial: no published results after enrollment closed in 2020.
[b]LORD trial: initial dual-arm randomization to surveillance versus surgery in 2016; changed in 2020 to a patient preference trial with single-arm enrollment in active surveillance only.
Abbreviations: BRCA = breast cancer gene; DCIS = ductal carcinoma in situ; IDC = invasive ductal carcinoma.

cancer.[26] However, if the early pathology literatures' progression rate in up to 39% of DCIS cases can be assumed, at least 61% of DCIS cases may be considered low risk.[5–7] Regardless of whether low risk DCIS constitutes 20% or 61% of all DCIS cases, the implications of doing less to treat low-risk DCIS affect many thousands of women each year with the potential to have a marked impact on mitigating the costs and morbidity associated with treating all DCIS cases as an invasive cancer. The recently published COMET trial data and future results of the remaining active surveillance trials should help patients and physicians make better data-driven decisions, tailored to the individual patient's inherent DCIS biology and preferences.

Demographics and presentation

The demographics of breast cancers are similar for both DCIS and invasive cancer, both occurring with an increasing incidence among older women. Because most DCIS are asymptomatic, outside the setting of high-risk screening in a younger woman less than 40 years of age, young women diagnosed with DCIS generally present with a palpable lump. Both because of age and the symptomatic nature of young women's DCIS, young women would be ineligible for active surveillance. Presumably, this is because young women's DCIS is considered at higher risk for progression. Symptomatic DCIS has a 35% upstage risk at surgical excision,[27] which is higher than the overall 25% upstage risk of all DCIS.[13] Yet, interestingly, in a cohort of young women with DCIS, despite 37% presenting with a palpable lump and often with larger size DCIS lesions, there were no differences in the distribution of DCIS grades and there was a relatively low recurrence rate of 6% observed at a median follow up of 8.4 years.[28] The relationship of age, size, grade, and palpability is complex. With regards to treatment of DCIS among young women, 76% opted for a mastectomy, often bilateral mastectomies, and only 13% continued endocrine therapy 1 year after the diagnosis of DCIS.[28] These observations give insight as it relates to concerns of overtreatment and the scope of nonadherence observed in daily practice.

Diagnosis: imaging and pathology

Because 90% of DCIS are asymptomatic, screening mammography has been the main contributor to its diagnosis,[29] although with the increasing use of ultrasound and breast MRI as supplemental screening tests, asymptomatic screen detected DCIS cases have been observed across all imaging modalities. All breast imaging modalities demonstrate both low-risk and high-risk DCIS cases, with a mixture of grades and presentation. Although some general knowledge has been gained in imaging-based prediction of what constitutes low versus high risk, in part assumed to be based on grade (Table 2), current shortcomings in imaging and subsequent pathology may be ameliorated in the future with developments in artificial intelligence applications.[30]

Mammography

Mammography is the imaging modality that best demonstrates suspicious microcalcifications. Because two thirds of

Table 2. Imaging characteristics of breast ductal carcinoma in situ (DCIS) by modality and grade.

Imaging modality	Low or intermediate grade	High grade	General features
Mammography	Amorphous grouped or new calcifications of any distribution	Fine pleomorphic, branching calcifications, segmental or ductal distribution	Calcifications, mass, asymmetry, or architectural distortion
Ultrasound	Mass or nonmass lesions without calcifications	Larger size, hypoechoic nonmass lesions with shadowing	Mass and nonmass lesions
Breast MRI	Mixed data regarding grade and MRI enhancement	Ultrafast MRI: shorter time to enhancement, greater maximum slope Diffusion-weighted imaging: low apparent diffusion coefficient	Segmental non-mass enhancement or enhancing mass Sensitivity for DCIS exceeds mammography Most accurate test for evaluating extent of disease
Contrast-enhanced mammography	Amorphous calcifications Enhancement	Fine pleomorphic or branching calcifications Enhancement	Noninferior sensitivity to breast MRI Combines features of digital mammography and MRI

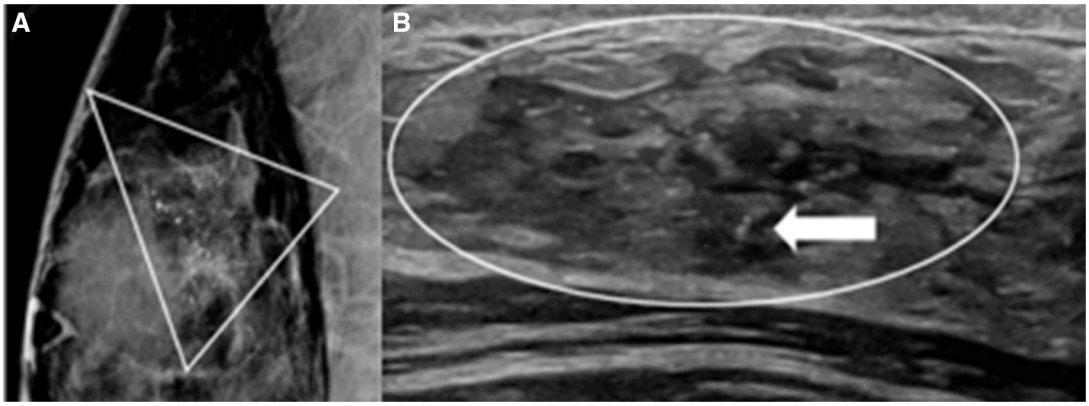

Figure 1. A 49-year-old woman presented with a palpable lump. (A) Medial-lateral mammogram shows a 3-cm area of segmental distribution (triangle) of fine, pleomorphic calcifications in the region of the palpable marker in the right superior breast. (B) Transverse gray scale ultrasound shows echogenic foci due to calcifications (arrow) within a hypoechoic nonmass lesion (oval). Ultrasound-guided biopsy revealed high-grade, estrogen receptor–negative ductal carcinoma in situ that was upstaged at surgery to multifocal invasive ductal carcinoma.

DCIS cases are at least partially calcified, widespread use of mammographic screening has resulted in the rising incidence of DCIS.[29] The approach to the assessment of calcifications has been described in the current 5th edition of the Mammography Breast Imaging Reporting and Data Systems lexicon with certain morphologies and distributions of calcifications attributed higher positive predictive values for cancer.[31] Accordingly, the morphology of microcalcifications has been reported to reflect the nuclear grade. Fine, pleomorphic or fine, linear branching calcifications (Figure 1) in a segmental, linear, or grouped distribution may reflect high-grade DCIS,[32,33] whereas amorphous or coarse heterogeneous microcalcifications may reflect lower grades of DCIS (Figure 2).[32–34]

The remaining one third of DCIS cases are noncalcified. Although noncalcified, mammography can demonstrate some of these DCIS cases, which may manifest as a mass (Figure 3), an asymmetry (Figure 4), an area of architectural distortion (Figure 5), or a dilated duct (Figure 6). Despite advances in mammography technology such as with digital breast tomosynthesis, the overall sensitivity of mammography for noncalcified DCIS remains limited, with sensitivity ranging from 56% to 68%.[32] Because of mammography's limited sensitivity, US and MRI play key roles in demonstrating the majority of noncalcified DCIS lesions.[35,36]

US

On ultrasound, pure DCIS without invasion may present as a mass or as a nonmass lesion.[37–39] US terminology of a nonmass lesion describes an area of altered echogenicity that lacks the convex margins of a space-occupying mass.[38] US nonmass lesions may correspond to a mammographic asymmetry (Figure 4B) or a region of architectural distortion (Figure 5B) and can have a nonspecific appearance, occurring in benign fibrocystic change, papillomatosis, DCIS, and invasive carcinomas. Among US-detected DCIS lesions, some conflicting reports of the grade of DCIS and US visibility exist, with 1 study indicating 70% of US-detected DCIS lesions presenting as a mass correlated with either low- or intermediate-grade DCIS,[40] and another study indicating that ER-negative, high-grade DCIS lesions were more likely to be visible on US.[41]

MRI

The equivalent of an US nonmass lesion is MRI nonmass enhancement, a finding that may occur secondary to both benign and malignant etiologies (Figure 7). Despite MRI's limitations and inability to show the microcalcifications of calcified DCIS, MRI has been reported to have a higher sensitivity than mammography for all DCIS lesions. Kuhl et al reported a 92% sensitivity of MRI for all DCIS, compared to

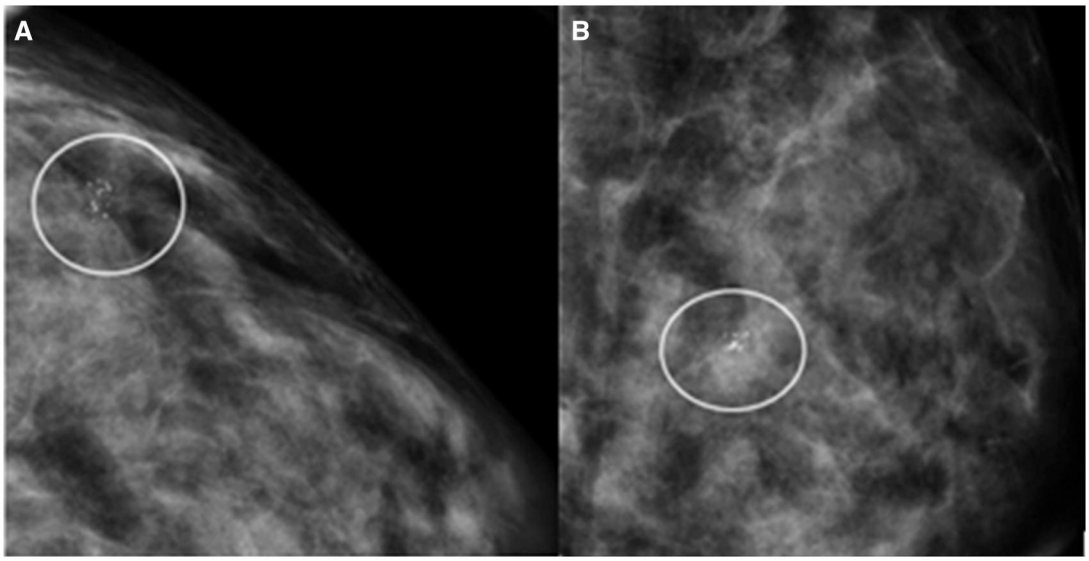

Figure 2. A 32-year-old woman presented for high-risk screening mammography. (A) Magnification craniocaudal mammogram demonstrates a 1-cm group of amorphous calcifications (circle) in the lateral breast. (B) Magnification medial-lateral mammogram demonstrates a 1-cm group of amorphous heterogeneous calcifications (circle) in the central breast. Stereotactic biopsy yielded estrogen receptor–positive, low-grade ductal carcinoma in situ that did not upstage at surgery; however, the calcifications reflected only half the true size of the low-grade DCIS, which was 2 cm at surgical excision.

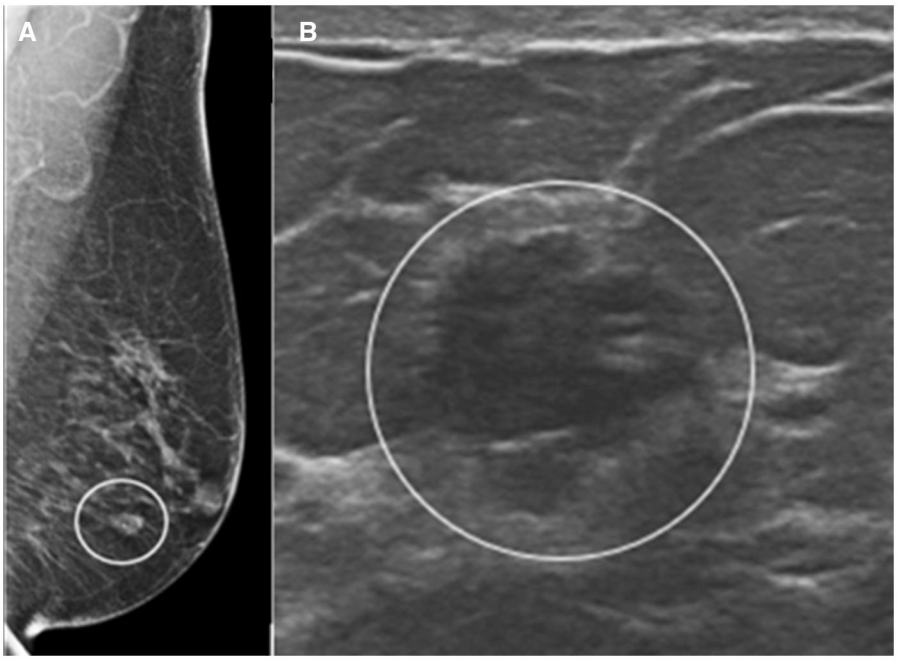

Figure 3. A 59-year-old woman presented for screening mammography with demonstration of a mass. (A) Mediolateral oblique mammogram performed after biopsy demonstrates an iso-dense, irregular, 1.2-cm mass with a biopsy clip (circle) in the left inferior breast. (B) Transverse gray scale ultrasound demonstrates an irregular, hypoechoic, round mass (circle) in the left breast at 5 o'clock, measuring 1.2 × 1.0 × 0.9 cm. Ultrasound-guided core biopsy yielded intermediate-grade ductal carcinoma in situ without necrosis, which was not upstaged at surgery.

mammography's overall sensitivity of 56%[42] (Figure 8). Although this information was reported more than a decade ago, later studies have validated MRI's high sensitivity, including a 2024 study that reported MRI's sensitivity for DCIS to be 93.9%, compared to mammography's sensitivity of 76.5%.[43] Although it is recognized that some calcified DCIS lesions do not demonstrate enhancement on MRI, it is also recognized that mammographic calcifications do not accurately reflect the extent of disease[44] (Figure 9). MRI has been shown to demonstrate additional sites of DCIS and is the most accurate test in estimating the true size of DCIS.[45–47] Finally, although it is generally assumed that grade correlates with vascular permeability and enhancement, Chou et al reported no differences in the MRI enhancement of low- and high-grade DCIS cases.[48]

Contrast-enhanced mammography

Hypothetically, the use of contrast-enhanced mammography (CEM) for the detection of DCIS should have advantages over either a digital breast tomosynthesis mammogram or an MRI because a CEM study consists of low-energy diagnostic mammogram images that demonstrate calcifications, and

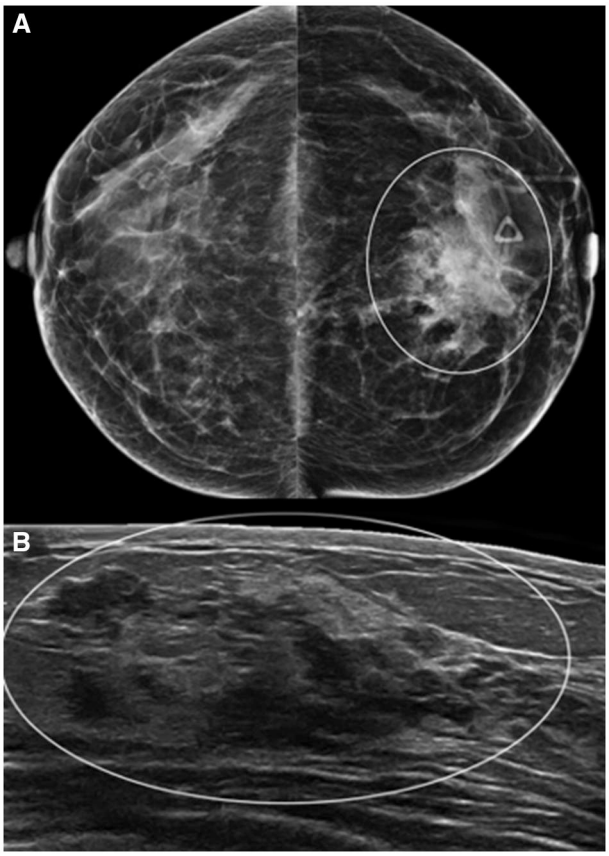

Figure 4. A 23-year-old woman with Li-Fraumeni syndrome presented with a palpable abnormality in the left breast. (A) Craniocaudal mammogram demonstrates a 5.3-cm area of global asymmetry (circle) in the left central breast at the site of the palpable marker (triangle). (B) Transverse gray scale ultrasound at the site of palpable abnormality demonstrates a 5-cm hypoechoic nonmass lesion (oval) in the left breast 11 to 1 o'clock region. Ultrasound-guided biopsy was initially sampled with a 14G spring-loaded core biopsy needle and then subsequently with a 9G vacuum-assisted biopsy needle in an attempt to preoperatively demonstrate the presence of an invasive cancer. Histopathology after both needle biopsies showed estrogen receptor–negative, high-grade ductal carcinoma in situ without invasion that was upstaged after mastectomy to multifocal microinvasive cancer with lymph node metastases.

reconstructed contrast-enhanced images that demonstrate areas of increased vascular enhancement. To date, there is limited literature on the use of CEM specifically for DCIS; however, based on a 2024 study directly comparing CEM and MRI in DCIS diagnosis, MRI had a slight advantage over CEM with a higher sensitivity for DCIS detection, although this difference was not statistically significant.[43] Nevertheless, as mammography is performed on all patients ultimately diagnosed with DCIS, whereas MRI is only selectively performed in some cases, CEM may ultimately prove to be the single most useful imaging test, harnessing the advantages conferred by both mammography and a vascular-based contrast enhanced examination.

Pathology

There are arbitrary pathologic differences between ADH and DCIS.[49] Even among breast pathology specialists, disagreement in the categorization of ADH and DCIS may be significant.[49] Early pathologic classification of DCIS described its architecture.[50] The architectural types can be categorized as comedo, solid, cribriform, papillary, and micropapillary; however, many DCIS histopathologic specimens contain a mixture of architectures and is not believed to be prognostically discriminatory. Categorization along the lines of nuclear grade based on the number of mitoses and the presence of necrosis may be more meaningful, although even this categorization may have limitations as there is only moderate agreement of the assigned grade among pathologists.[51–53] At the molecular level, scientists now recognize a subset of DCIS with more biologically aggressive behaviors based on the molecular subtype and recommend pathologists report the ER and the human epidermal receptor 2 (HER2) expression of DCIS, if the pathology of the final surgical excision shows no invasive cancer. Just as in invasive cancers, identifying these molecular subtypes of DCIS may be important. Biomarker receptor testing among DCIS lesions may be used to tailor further therapies, including omitting endocrine therapies in the 18% of DCIS that are ER negative[41] and potentially adding targeted HER2-based therapies in the 22% of DCIS that are HER2 positive,[54] although these practices are currently not the standard of care.

Treatments

Per the National Comprehensive Cancer Network (NCCN) guidelines, the current standard-of-care treatment of DCIS remains surgical excision of the DCIS, sentinel lymph node biopsy if the patient elects for a mastectomy, radiation therapy in the setting of breast-conserving surgery, and endocrine treatment in the majority of DCIS that are ER positive.[55] In the following sections, each treatment arm will be reviewed.

Surgery

Surgical lumpectomy or mastectomy of DCIS serves the purpose of removing the source of DCIS that could later progress into an invasive cancer, while simultaneously diagnosing a coexisting occult invasive cancer. The size of the DCIS, relative to the size of the whole breast, is a key determinant in a patient's choice between breast-conserving lumpectomy versus mastectomy. If the DCIS is not extensive, breast-conserving lumpectomy may be performed with the goal of at least a 2-mm negative margin,[56] although a smaller and narrower margin of 1 mm may be sufficient if radiation therapy is administered.[57] On the other hand, 17% of DCIS cases are extensive,[58] necessitating a mastectomy. A patient's choice for mastectomy is multifactorial and includes other considerations besides the size of DCIS, including personal preferences and/or aversions to radiation and endocrine treatments, as well as available reconstructive options. Despite DCIS representing a disease state along the continuum of a high-risk breast lesion or the earliest stage of breast cancer, up to 31% of DCIS patients choose the more radical breast surgery option of a mastectomy.[59]

Sentinel lymph node biopsy (SLNB) represents an overtreatment in the 96% of DCIS cases that are without lymph node metastasis.[60] Although NCCN guidelines recommend either SLNB at the time of mastectomy or as a second surgical procedure in only those DCIS cases upstaged to an invasive cancer following breast-conserving lumpectomy,[55] in clinical practice, there is moderate variability in the application of such recommendations. SLNB is often performed upfront at the time of breast-conserving lumpectomy, based on a surgeon's level of suspicion for invasion. For example, a group from South Korea reported that SLNB was performed in

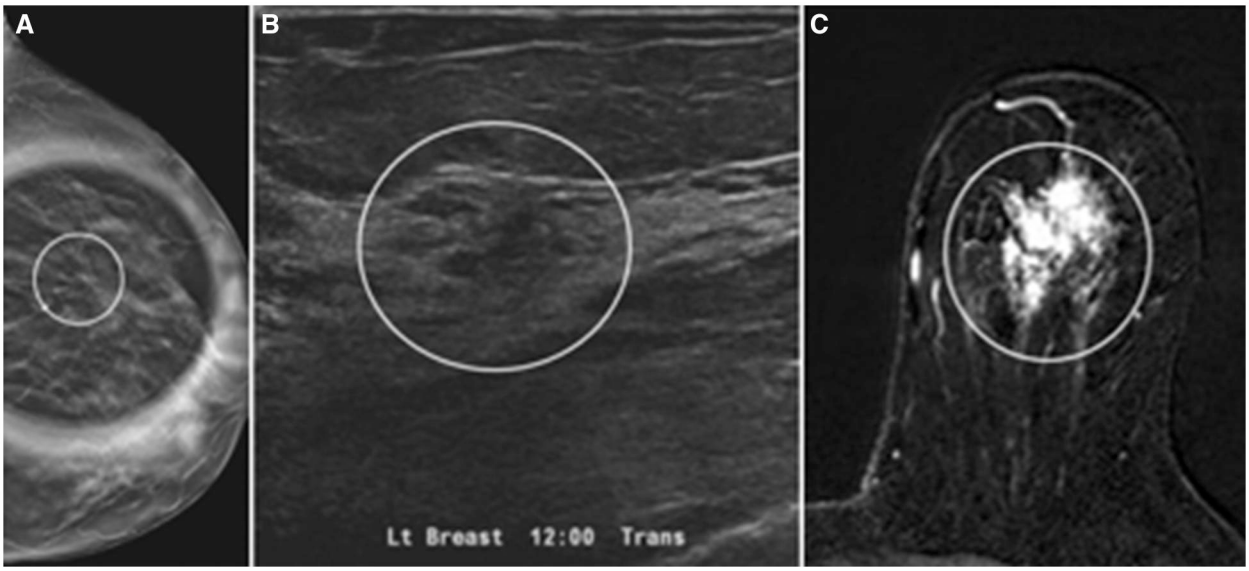

Figure 5. A 67-year-old woman presented for screening mammography with demonstration of architectural distortion. (A) Medial-lateral spot compression digital breast tomosynthesis mammogram shows a 1.5-cm architectural distortion (circle) in the left superior breast. (B) Transverse gray scale ultrasound shows a nonspecific 1.6 × 1.5 × 0.7 cm hypoechoic, nonmass lesion (circle) in the left breast 12 o'clock region. Because the more suspicious imaging finding was the mammographic distortion, a digital breast tomosynthesis-guided vacuum-assisted biopsy was performed and yielded intermediate-grade ductal carcinoma in situ. (C) Axial T1-weighted gadolinium enhanced MRI shows a 4.3 × 3.5 × 3.2 cm area of heterogeneous nonmass enhancement (circle), larger than the size of mammographic distortion and ultrasound nonmass lesion. At surgery, there was no invasive cancer and the ductal carcinoma in situ size was 3.5 × 2.8 × 0.6 cm, as predicted by the size of MRI enhancement.

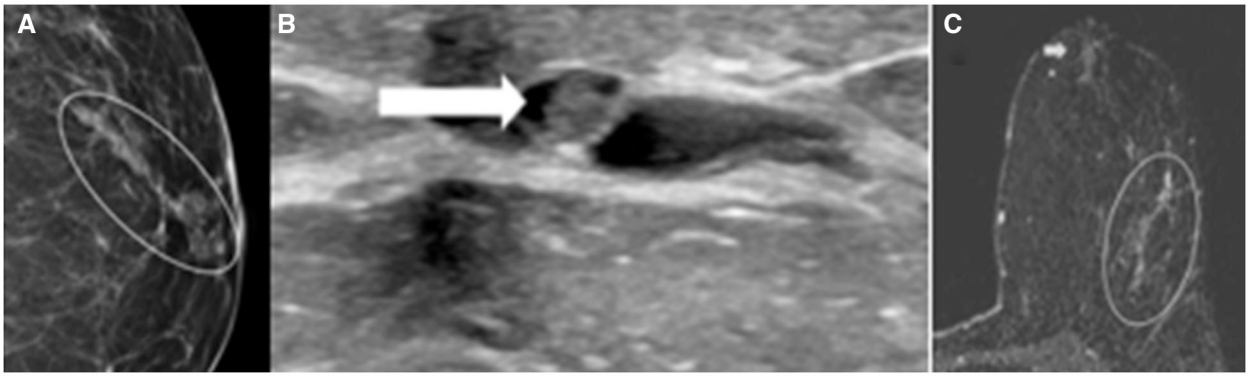

Figure 6. A 60-year-old woman presented for screening mammography, with demonstration of a dilated duct. (A) Mediolateral oblique mammogram demonstrates new solitary dilated duct (oval) in the subareolar region of the left breast. (B) Transverse-gray scale ultrasound of the subareolar region demonstrates an intraductal mass (arrow) within a dilated duct. Ultrasound-guided core needle biopsy yielded intermediate-grade ductal carcinoma in situ. (C) Axial fat-suppressed T1-weighted gadolinium-enhanced MRI shows more extensive disease than mammography and ultrasound. MRI shows nonmass enhancement at the site of the ultrasound-guided biopsy-proven ductal carcinoma in situ in the left breast subareolar region (arrow) and an additional left breast 2 to 3 o'clock linear and segmental nonmass enhancement posteriorly (oval). MRI-guided biopsy of the more posterior nonmass enhancement (oval) revealed intermediate-grade ductal carcinoma in situ, confirming multifocal disease. Mastectomy showed no evidence of invasive cancer.

37.2% of lumpectomies and 94.1% of mastectomies, and 71.2% of all SLNBs in this group proved to be unnecessary because there was no invasive cancer at final surgery.[61] To help guide the decision to include SLNB at the time of lumpectomy for DCIS, the risk of lymph node metastases may be calculated with the DCIS-met model. The DCIS-met model has been validated with a moderate area under the curve of 0.74 and considers multiple variables including the patient's age, the mode of detection, palpability, mammography Breast Imaging Reporting and Data Systems (BI-RADS) assessment, nuclear grade, and the histopathology report to estimate the overall probability of lymph node metastasis.[62]

Radiation therapy

Because of the excellent prognosis of surgically treated DCIS, the use of any adjuvant treatment has been challenged as a form of overtreatment. With breast lumpectomy alone, there is a 14.4%–24.6% recurrence rate of either DCIS or invasive cancer at 12-year follow-up.[63] Adjuvant radiation therapy results in a 52% reduction in this recurrence rate, although without reductions in the breast cancer–specific or all-cause mortality rate.[64] To help guide the decision to proceed with radiation therapy or not, two molecular bioassay tools have been developed, although widespread application may be limited because of cost. The first is DCISion RT (Prelude Dx,

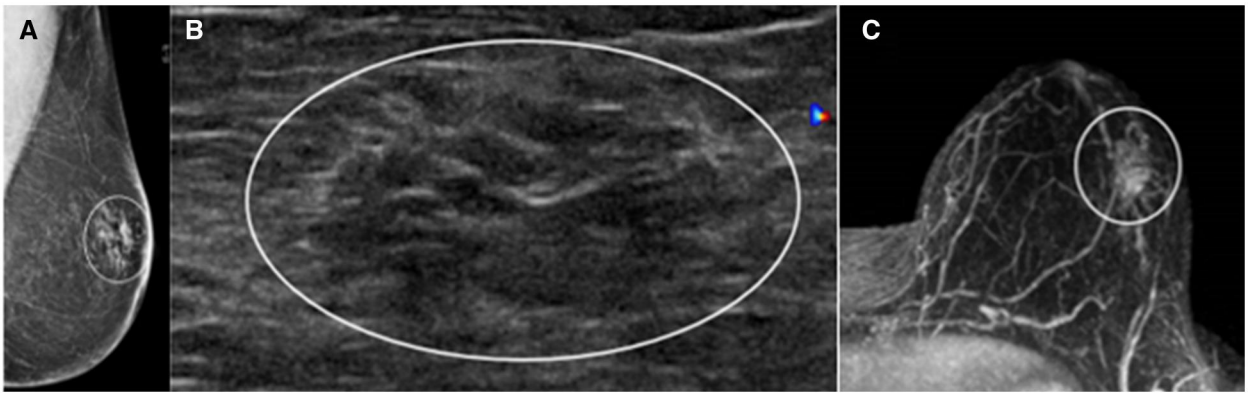

Figure 7. A 49-year-old woman presented with a palpable lump in the left lateral breast. (A) Mediolateral oblique mammogram shows an asymmetry (oval) in the region of the palpable marker. (B) Longitudinal gray scale ultrasound shows a 2.3 × 2.1 × 1.5 cm nonmass lesion consisting of dilated tubular ducts (oval) in the left breast at 3 o'clock. The imaging appearance is nonspecific and overlaps with benign fibrocystic change. Ultrasound-guided biopsy revealed intermediate-grade ductal carcinoma in situ. (C) Maximum intensity projection MRI shows a 2.3-cm area of focal nonmass enhancement (circle) in the left breast at 3 o'clock, which corresponds to the ultrasound nonmass lesion representing dilated tubular ducts. At surgical lumpectomy, there was no invasive cancer.

Figure 8. A 61-year-old woman presented for high-risk screening with both mammography and MRI. (A) Implant-displaced craniocaudal and mediolateral oblique screening mammograms demonstrate no suspicious mammographic masses, asymmetries, architectural distortions, or calcifications. (B) Maximum intensity projection image from a screening MRI demonstrates marked asymmetric, diffuse right breast nonmass enhancement (circle). MRI-guided biopsy yielded intermediate grade, estrogen receptor–negative ductal carcinoma in situ with associated comedonecrosis, which was subsequently upstaged to an invasive ductal cancer at mastectomy.

Laguna Hills, CA), which utilizes a 7-protein immunohistochemical assay combined with 4 clinical parameters (age, palpability, size, and margin status), the presence or absence of a Kirsten rat sarcoma virus–activated pathway, and residual risk subtype (RRt) to determine a DCISion RT score of 0–10. If the score is ≤2.8 with no RRt, radiation therapy is unlikely

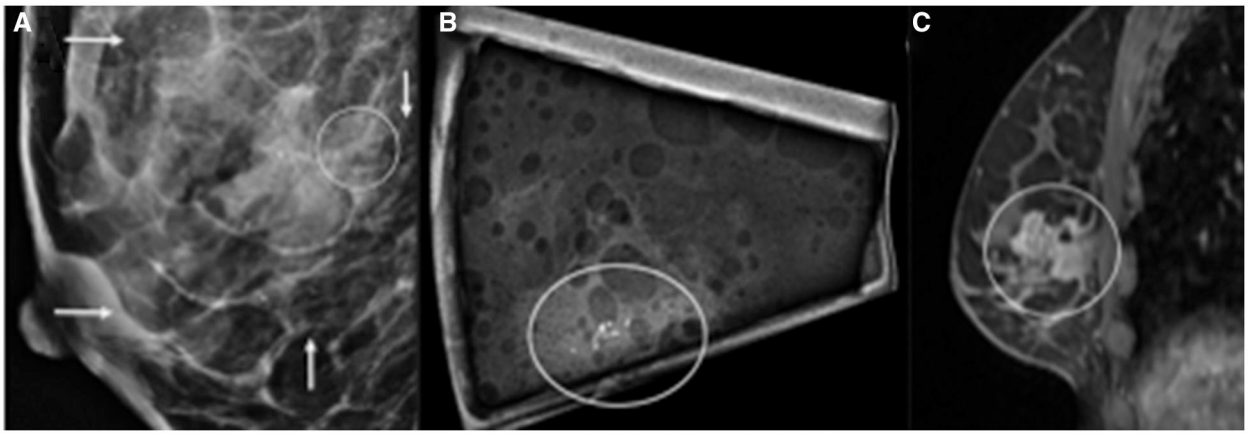

Figure 9. A 60-year-old woman with a 5.5-cm area of calcifications, within which some new calcifications had developed. (A) Magnified medial-lateral mammogram demonstrates a 5.5-cm area of calcifications (arrows). Some of the calcifications were unchanged for several years. Within this large area of calcifications, stereotactic biopsy was recommended to sample calcifications demonstrating definite interval development (circle). (B) Specimen radiograph demonstrates retrieval of coarse heterogeneous calcifications. Pathology yielded intermediate grade DCIS. (C) Sagittal fat suppressed T1-weighted gadolinium-enhanced MRI performed after stereotactic biopsy demonstrates a 3.5 × 2.6 × 3.2 cm area of nonmass enhancement (oval), smaller than the initially described 5.5-cm area of calcifications and on further review correlated with the size of the new calcifications.

to be of benefit and the DCIS is considered low risk for recurrence. If the score is >2.8 with RRt, radiation therapy is recommended because the DCIS is considered high risk for recurrence. The intermediate-risk group consists of a score ≥2.8 without RRt.[65] The other molecular bioassay tool is Oncotype DX DCIS (Genomic Health, Redwood City, CA) which is a 12-gene assay selected from the larger 21-gene assay panel used in invasive cancers to determine the 10-year ipsilateral local recurrence risk for DCIS treated with breast-conserving surgery alone without radiation. Based on a score of 0–100, low risk is defined by a score less than 39, high risk by a score greater than 55, and intermediate risk by a score between 39 and 54; the Oncotype DX DCIS score is used to rationalize a decision to either proceed or forego radiation.[66]

Endocrine therapy

Antiestrogen endocrine therapy has become the mainstay of breast cancer prevention in women who are diagnosed with high-risk breast lesions such as ADH and lobular neoplasias and for the 82% of DCIS cases that are ER positive.[39] Unlike radiation therapy to the ipsilateral breast only, endocrine therapy has the advantage of reducing the risk of recurrence in both breasts.[67] Adherence to endocrine treatment recommendation, however, may be limited because of multiple side effects of antiestrogens, including vasomotor instability, risk of thrombosis, endometrial hyperplasia, arthralgias, osteopenia, and effects on libido and cognition. One study reported as many as 20% of patients reported cessation of tamoxifen during the first 5 years of recommended therapy.[68] Furthermore, young patients and those with pure DCIS without invasive cancers are more likely to decline endocrine therapy, with only 40% of patients reported to be adherent at 5 years after the diagnosis of DCIS.[69]

Conclusion

The major criticisms of screening mammography relate to overdiagnosis and overtreatment. At the current time, overdiagnosis is unavoidable unless a radiologist purposefully tries not to find cancers, something that is contrary to one of the goals and metrics of interpretation. A radiologist who appropriately detects an imaging finding that ultimately leads to a diagnosis of DCIS is doing his or her job to detect a condition that, if managed appropriately, could prevent death from breast cancer. Future developments in artificial intelligence and screening applications of existing tests such as CEM may decrease overdiagnosis by improving the specificity without loss in sensitivity. Until then, efforts should be placed on avoiding overtreatment, which is only possible if radiologists, treating physicians, and patients conceptualize DCIS as a heterogeneous disease with variable outcomes warranting differential treatments.

At the current time, nonsurgical treatment of DCIS has been reserved for those enrolled in an active surveillance clinical trial. Clinicians and patients have been reluctant to accept doing less than the current NCCN guidelines to undergo surgery and additional therapies, but treatment recommendations are expected to evolve, especially in light of the recently published COMET trial outcomes.[22] The goal of DCIS treatment should continue to be as efficacious as the current treatment regimens that effectively minimize the mortality of breast cancer but also contribute to morbidity. The goal of DCIS treatment should also endeavor to avoid overtreatment by personalizing care that may include surveillance as a viable, safe alternative treatment option in a subset of DCIS cases. This approach can have an enormous impact on mitigating some of the physical, psychological, and financial costs of overtreatment that are currently in place.

Author contributions

Hannah Chung (Conceptualization, Formal analysis, Methodology, Project administration)

Supplementary material

Supplementary material is available at *Radiology Advances* online.

Funding

None declared.

Conflicts of interest

Please see ICMJE form(s) for author conflicts of interest. These have been provided as supplementary materials. No conflicts of interest to disclose.

References

1. Virnig BA, Tuttle TM, Shamliyan T, Kane RL. Ductal carcinoma in situ of the breast: a systematic review of incidence, treatment, and outcomes. *J Natl Cancer Inst*. 2010;102(3):170-178. https://doi.org/10.1093/jnci/djp482
2. Giaquinto AN, Sung H, Newman LA, et al. Breast cancer statistics 2024. *CA Cancer J Clin*. 2024;74(6):477-495. https://doi.org/10.3322/caac.21863
3. Thomas ET, Del Mar C, Glasziou P, Wright G, Barratt A, Bell KJL. Prevalence of incidental breast cancer and precursor lesions in autopsy studies: a systematic review and meta-analysis. *BMC Cancer*. 2017;17(1):808. https://doi.org/10.1186/s12885-017-3808-1
4. Ryser MD, Worni M, Turner EL, Marks JR, Durrett R, Hwang ES. Outcomes of active surveillance for ductal carcinoma in situ: a computational risk analysis. *J Natl Cancer Inst*. 2016;108(5):djv372. https://doi.org/10.1093/jnci/djv372
5. Sanders ME, Schuyler PA, Dupont WD, Page DL. The natural history of low-grade ductal carcinoma in situ of the breast in women treated by biopsy only revealed over 30 years of long-term follow-up. *Cancer*. 2005;103(12):2481-2484. https://doi.org/10.1002/cncr.21069
6. Sanders ME, Schuyler PA, Simpson JF, Page DL, Dupont WD. Continued observation of the natural history of low-grade ductal carcinoma in situ reaffirms proclivity for local recurrence even after more than 30 years of follow-up. *Mod Pathol*. 2015;28(5):662-669. https://doi.org/10.1038/modpathol.2014.141
7. Betsill WL Jr, Rosen PP, Lieberman PH, Robbins GF. Intraductal carcinoma. Long-term follow-up after treatment by biopsy alone. *JAMA*. 1978;239(18):1863-1867. https://doi.org/10.1001/jama.239.18.1863
8. Casasent AK, Schalck A, Gao R, et al. Multiclonal invasion in breast tumors identified by topographic single cell sequencing. *Cell*. 2018;172(1-2):205-217.e12. https://doi.org/10.1016/j.cell.2017.12.007
9. Borowsky A, Glencer A, Ramalingam K, et al. Tumor microenvironmental determinants of high-risk DCIS progression. *Res Sq*. 2024;rs.3.rs-4126092. https://doi.org/10.21203/rs.3.rs-4126092/v1
10. Ryser MD, Weaver DL, Zhao F, et al. Cancer outcomes in DCIS patients without locoregional treatment. *J Natl Cancer Inst*. 2019;111(9):952-960. https://doi.org/10.1093/jnci/djy220
11. Sherman ME, Vierkant RA, Winham SJ, et al. Benign breast disease and breast cancer risk in the percutaneous biopsy era. *JAMA Surg*. 2024;159(2):193-201. https://doi.org/10.1001/jamasurg.2023.6382
12. Sokolova A, Lakhani SR. Lobular carcinoma in situ: diagnostic criteria and molecular correlates. *Mod Pathol*. 2021;34(Suppl 1):8-14. https://doi.org/10.1038/s41379-020-00689-3
13. Brennan ME, Turner RM, Ciatto S, et al. Ductal carcinoma in situ at core-needle biopsy: meta-analysis of underestimation and predictors of invasive breast cancer. *Radiology*. 2011;260(1):119-128. https://doi.org/10.1148/radiol.11102368
14. Willers N, Neven P, Floris G, et al. The upgrade risk of B3 lesions to (pre)invasive breast cancer after diagnosis on core needle or vacuum assisted biopsy. A Belgian national cohort study. *Clin Breast Cancer*. 2023;23(4):e273-e280. https://doi.org/10.1016/j.clbc.2023.03.006
15. Murray MP, Luedtke C, Liberman L, Nehhozina T, Akram M, Brogi E. Classic lobular carcinoma in situ and atypical lobular hyperplasia at percutaneous breast core biopsy: outcomes of prospective excision. *Cancer*. 2013;119(5):1073-1079. https://doi.org/10.1002/cncr.27841
16. Neuman HB, Wilke LG, Bozzuto LM, et al. Engaging multidisciplinary teams to develop pragmatic clinical practice guidelines to support management of patients with high-risk breast lesions. *Clin Breast Cancer*. 2025;25(1):56-64. https://doi.org/10.1016/j.clbc.2024.10.003
17. Xie CL, Whitman GJ, Middleton LP, Bevers TB, Bedrosian I, Chung HL. Isolated flat epithelial atypia: upgrade outcomes after multidisciplinary review-based management using excision or imaging surveillance. *J Breast Imaging*. 2023;5(5):575-584. https://doi.org/10.1093/jbi/wbad049.
18. Greene AJE, Davis J, Moon J, et al. Determination of factors associated with upstage in atypical ductal hyperplasia to identify low-risk patients where active surveillance may be an alternative. *Ann Surg Oncol*. 2024;31(5):3177-3185. https://doi.org/10.1245/s10434-024-15041-1
19. Han LK, Hussain A, Dodelzon K, Ginter PS, Towne WS, Marti JL. Active surveillance of atypical ductal hyperplasia of the breast. *Clin Breast Cancer*. 2023;23(6):649-657. https://doi.org/10.1016/j.clbc.2023.05.008
20. Matias MA, Sharma N. Nonsurgical management of high-risk lesions. *Radiol Clin North Am*. 2024;62(4):679-686. https://doi.org/10.1016/j.rcl.2023.12.005
21. Chung HL, Middleton LP, Sun J, Whitman GJ. Immediate and delayed risk of breast cancer associated with classic lobular carcinoma in situ and its variants. *Breast Cancer Res Treat*. 2024;205(3):545-554. https://doi.org/10.1007/s10549-024-07261-6
22. Hwang ES, Hyslop T, Lynch T, et al.; COMET Study Investigators. Active monitoring with or without endocrine therapy for low-risk ductal carcinoma in situ: the COMET randomized clinical trial. *JAMA*. 2024; Dec 12. https://doi.org/10.1001/jama.2024.26698
23. Elshof LE, Tryfonidis K, Slaets L, et al. Feasibility of a prospective, randomised, open-label, international multicentre, phase III, non-inferiority trial to assess the safety of active surveillance for low risk ductal carcinoma in situ—the LORD study. *Eur J Cancer*. 2015;51(12):1497-1510. https://doi.org/10.1016/j.ejca.2015.05.008
24. Francis A, Fallowfield L, Rea D. The LORIS Trial: addressing overtreatment of ductal carcinoma in situ. *Clin Oncol (R Coll Radiol)*. 2015;27(1):6-8. https://doi.org/10.1016/j.clon.2014.09.015
25. Kanbayashi C, Iwata H. Current approach and future perspective for ductal carcinoma in situ of the breast. *Jpn J Clin Oncol*. 2017;47(8):671-677. https://doi.org/10.1093/jjco/hyx059
26. McAdams CD, Clevenger N, Nicholson K, et al. Proportion of patients with ductal carcinoma in situ that qualify for observation criteria set forth by clinical trials. *J Surg Oncol*. 2024. https://doi.org/10.1002/jso.27858
27. Venkatesh SL, Oseni TO, Bahl M. Symptomatic ductal carcinoma in situ (DCIS): upstaging risk and predictors. *Clin Imaging*. 2021;73:101-107. https://doi.org/10.1016/j.clinimag.2020.11.050
28. Tesch ME, Rosenberg SM, Collins LC, et al. Clinicopathologic features, treatment patterns, and disease outcomes in a modern, prospective cohort of young women diagnosed with ductal carcinoma in situ. *Ann Surg Oncol*. 2022;29(13):8048-8057. https://doi.org/10.1245/s10434-022-12361-y
29. Gangnon RE, Sprague BL, Stout NK, et al. The contribution of mammography screening to breast cancer incidence trends in the United States: an updated age-period-cohort model. *Cancer Epidemiol Biomarkers Prev*. 2015;24(6):905-912. https://doi.org/10.1158/1055-9965.EPI-14-1286
30. Uchikov P, Khalid U, Dedaj-Salad GH, et al. Artificial Intelligence in breast cancer diagnosis and treatment: advances in imaging, pathology, and personalized care. *Life (Basel)*. 2024;14(11):1451. https://doi.org/10.3390/life14111451
31. D'Orsi CJ, Mendelson EB, Morris EA. *ACR BI-RADS® Atlas, Breast Imaging Reporting and Data System*. American College of Radiology; 2013.
32. van Leeuwen MM, Doyle S, van den Belt-Dusebout AW, et al. Clinicopathological and prognostic value of calcification morphology descriptors in ductal carcinoma in situ of the breast: a

systematic review and meta-analysis. *Insights Imaging*. 2023;14(1):213. https://doi.org/10.1186/s13244-023-01529-z.
33. Hofvind S, Iversen BF, Eriksen L, Styr BM, Kjellevold K, Kurz KD. Mammographic morphology and distribution of calcifications in ductal carcinoma in situ diagnosed in organized screening. *Acta Radiol*. 2011;52(5):481-487. https://doi.org/10.1258/ar.2011.100357
34. Holland R, Hendriks JH. Microcalcifications associated with ductal carcinoma in situ: mammographic-pathologic correlation. *Semin Diagn Pathol*. 1994;11(3):181-192.
35. Lamb LR, Kim G, Oseni TO, Bahl M. Noncalcified ductal carcinoma in situ (DCIS): rate and predictors of upgrade to invasive carcinoma. *Acad Radiol*. 2021;28(3):e71-e76. https://doi.org/10.1016/j.acra.2020.02.011
36. Kim JH, Ko ES, Kim DY, Han H, Sohn JH, Choe DH. Noncalcified ductal carcinoma in situ: imaging and histologic findings in 36 tumors. *J Ultrasound Med*. 2009;28(7):903-910. https://doi.org/10.7863/jum.2009.28.7.903
37. Wang LC, Sullivan M, Du H, Feldman MI, Mendelson EB. US appearance of ductal carcinoma in situ. *Radiographics*. 2013;33(1):213-228. https://doi.org/10.1148/rg.331125092
38. Choe J, Chikarmane SA, Giess CS. Nonmass findings at breast US: definition, classifications, and differential diagnosis. *Radiographics*. 2020;40(2):326-335. https://doi.org/10.1148/rg.2020190125
39. Moschetta M, Sardaro A, Nitti A, et al. Ultrasound evaluation of ductal carcinoma in situ of the breast. *J Ultrasound*. 2022;25(1):41-45. https://doi.org/10.1007/s40477-020-00551-x
40. Ben Khadra S, Hacking SM, Carpentier B, et al. Mass-forming ductal carcinoma in situ: an ultrasonographic and histopathologic correlation study. *Pathol Res Pract*. 2022;237:154035. https://doi.org/10.1016/j.prp.2022.154035
41. Rauch GM, Kuerer HM, Scoggins ME, et al. Clinicopathologic, mammographic, and sonographic features in 1,187 patients with pure ductal carcinoma in situ of the breast by estrogen receptor status. *Breast Cancer Res Treat*. 2013;139(3):639-647. https://doi.org/10.1007/s10549-013-2598-7
42. Kuhl CK, Schrading S, Bieling HB, et al. MRI for diagnosis of pure ductal carcinoma in situ: a prospective observational study. *Lancet*. 2007;370(9586):485-492. https://doi.org/10.1016/S0140-6736(07)61232-X
43. Wang L, Wang P, Shao H, Li J, Yang Q. Role of contrast-enhanced mammography in the preoperative detection of ductal carcinoma in situ of the breasts: a comparison with low-energy image and magnetic resonance imaging. *Eur Radiol*. 2024;34(5):3342-3351. https://doi.org/10.1007/s00330-023-10312-z
44. Holland R, Hendriks JH, Vebeek AL, Mravunac M, Schuurmans Stekhoven JH. Extent, distribution, and mammographic/histological correlations of breast ductal carcinoma in situ. *Lancet*. 1990;335(8688):519-522. https://doi.org/10.1016/0140-6736(90)90747-s
45. Kuhl CK, Strobel K, Bieling H, et al. Impact of preoperative breast MR imaging and MR-guided surgery on diagnosis and surgical outcome of women with invasive breast cancer with and without DCIS component. *Radiology*. 2017;284(3):645-655. https://doi.org/10.1148/radiol.2017161449
46. Preibsch H, Beckmann J, Pawlowski J, et al. Accuracy of breast magnetic resonance imaging compared to mammography in the preoperative detection and measurement of pure ductal carcinoma in situ: a retrospective analysis. *Acad Radiol*. 2019;26(6):760-765. https://doi.org/10.1016/j.acra.2018.07.013
47. Lamb LR, Oseni TO, Lehman CD, Bahl M. Pre-operative MRI in patients with ductal carcinoma in situ: is MRI useful for identifying additional disease? *Eur J Radiol*. 2020;129:109130. https://doi.org/10.1016/j.ejrad.2020.109130
48. Chou SS, Gombos EC, Chikarmane SA, Giess CS, Jayender J. Computer-aided heterogeneity analysis in breast MR imaging assessment of ductal carcinoma in situ: correlating histologic grade and receptor status. *J Magn Reson Imaging*. 2017;46(6):1748-1759. https://doi.org/10.1002/jmri.25712
49. Tozbikian G, Brogi E, Vallejo CE, et al. Atypical ductal hyperplasia bordering on ductal carcinoma in situ. *Int J Surg Pathol*. 2017;25(2):100-107. https://doi.org/10.1177/1066896916662154
50. The Consensus Conference Committee. Consensus conference on the classification of ductal carcinoma in situ. *Cancer*. 1997;80(9):1798-1802. https://doi.org/10.1002/(sici)1097-0142(19971101)80:9<1798:aid-cncr15>3.0.co;2-0
51. Cserni G, Sejben A. Grading ductal carcinoma in situ (DCIS) of the breast—what's wrong with it? *Pathol Oncol Res*. 2020;26(2):665-671. https://doi.org/10.1007/s12253-019-00760-8
52. Van Bockstal MR, Berlière M, Duhoux FP, Galant C. Interobserver variability in ductal carcinoma in situ of the breast. *Am J Clin Pathol*. 2020;154(5):596-609.
53. van Seijen M, Jóźwiak K, Pinder SE, et al. Grand Challenge PRECISION consortium. Variability in grading of ductal carcinoma in situ among an international group of pathologists. *J Pathol Clin Res*. 2021;7(3):233-242.
54. Schandiz H, Park D, Kaiser YL, et al. Subtypes of high-grade breast ductal carcinoma in situ (DCIS): incidence and potential clinical impact. *Breast Cancer Res Treat*. 2023;201(2):329-338. https://doi.org/10.1007/s10549-023-07016-9
55. National Comprehensive Cancer Network: Breast Cancer (Version 4.2024). Accessed July 10, 2024. https://www.nccn.org/guidelines/guidelines-detail?category=1&id=1419
56. Morrow M, Van Zee KJ, Solin LJ, et al. Society of Surgical Oncology-American Society for Radiation Oncology-American Society of Clinical Oncology consensus guideline on margins for breast-conserving surgery with whole-breast irradiation in ductal carcinoma in situ. *Ann Surg Oncol*. 2016;23(12):3801-3810. https://doi.org/10.1245/s10434-016-5449-z
57. Tadros AB, Smith BD, Shen Y, et al. Ductal carcinoma in situ and margins <2 mm: contemporary outcomes with breast conservation. *Ann Surg*. 2019;269(1):150-157. https://doi.org/10.1097/SLA.0000000000002439
58. Alexander M, Beyda J, Nayak A, Jaffer S. Not all ductal carcinomas in situ are created IDLE (indolent lesions of epithelial origin). *Arch Pathol Lab Med*. 2019;143(1):99-104. https://doi.org/10.5858/arpa.2017-0366-OA
59. Byun DJ, Wu SP, Nagar H, Gerber NK. Ductal carcinoma in situ in young women: increasing rates of mastectomy and variability in endocrine therapy use. *Ann Surg Oncol*. 2021;28(11):6083-6096. https://doi.org/10.1245/s10434-021-09972-2
60. Gooch JC, Schnabel F, Chun J, et al. A nomogram to predict factors associated with lymph node metastasis in ductal carcinoma in situ with microinvasion. *Ann Surg Oncol*. 2019;26(13):4302-4309. https://doi.org/10.1245/s10434-019-07750-9
61. Shin YD, Lee HM, Choi YJ. Necessity of sentinel lymph node biopsy in ductal carcinoma in situ patients: a retrospective analysis. *BMC Surg*. 2021;21(1):159. https://doi.org/10.1186/s12893-021-01170-x
62. Meurs CJC, van Rosmalen J, Menke-Pluijmers MBE, Siesling S, Westenend PJ. Predicting lymph node metastases in patients with biopsy-proven ductal carcinoma in situ of the breast: development and validation of the DCIS-met model. *Ann Surg Oncol*. 2023;30(4):2142-2151. https://doi.org/10.1245/s10434-022-12900-7
63. Solin LJ, Gray R, Hughes LL, et al. Surgical excision without radiation for ductal carcinoma in situ of the breast: 12-year results from the ECOG-ACRIN E5194 study. *J Clin Oncol*. 2015;33(33):3938-3944. https://doi.org/10.1200/JCO.2015.60.8588.
64. Wapnir IL, Dignam JJ, Fisher B, et al. Long-term outcomes of invasive ipsilateral breast tumor recurrences after lumpectomy in NSABP B-17 and B-24 randomized clinical trials for DCIS. *J Natl Cancer Inst*. 2011;103(6):478-488. https://doi.org/10.1093/jnci/djr027
65. Shah C, Bremer T, Cox C, et al. The clinical utility of DCISionRT on radiation therapy decision making in patients with ductal carcinoma in situ following breast-conserving surgery. *Ann Surg Oncol*. 2021;28(11):5974-5984. https://doi.org/10.1245/s10434-021-09903-1. Erratum in: *Ann Surg Oncol*. 2021;28(Suppl 3):878. https://doi.org/10.1245/s10434-021-10138-3

66. Van Zee KJ, Zabor EC, Di Donato R, et al. Comparison of local recurrence risk estimates after breast-conserving surgery for DCIS: DCIS nomogram versus refined oncotype DX breast DCIS score. *Ann Surg Oncol*. 2019;26(10):3282-3288. https://doi.org/10.1245/s10434-019-07537-y
67. Fisher B, Land S, Mamounas E, Dignam J, Fisher ER, Wolmark N. Prevention of invasive breast cancer in women with ductal carcinoma in situ: an update of the National Surgical Adjuvant Breast and Bowel Project experience. *Semin Oncol*. 2001;28(4):400-418. https://doi.org/10.1016/s0093-7754(01)90133-2
68. Karavites LC, Kane AK, Zaveri S, et al. Tamoxifen acceptance and adherence among patients with ductal carcinoma in situ (DCIS) treated in a multidisciplinary setting. *Cancer Prev Res (Phila)*. 2017;10(7):389-397. https://doi.org/10.1158/1940-6207.CAPR-17-0029
69. Ward KA, Muller DA, Dutta SW, et al. Long-term adherence to adjuvant endocrine therapy following various radiotherapy modalities in early stage hormone receptor positive breast cancer. *Clin Breast Cancer*. 2023;23(4):369-377. https://doi.org/10.1016/j.clbc.2023.01.012

© The Author(s) 2025. Published by Oxford University Press on behalf of the Radiological Society of North America.
This is an Open Access article distributed under the terms of the Creative Commons Attribution-NonCommercial License (https://creativecommons.org/licenses/by-nc/4.0/), which permits non-commercial re-use, distribution, and reproduction in any medium, provided the original work is properly cited. For commercial re-use, please contact reprints@oup.com for reprints and translation rights for reprints. All other permissions can be obtained through our RightsLink service via the Permissions link on the article page on our site—for further information please contact journals.permissions@oup.com.
Radiology Advances, 2025, 2, 1–12
https://doi.org/10.1093/radadv/umaf007
Review